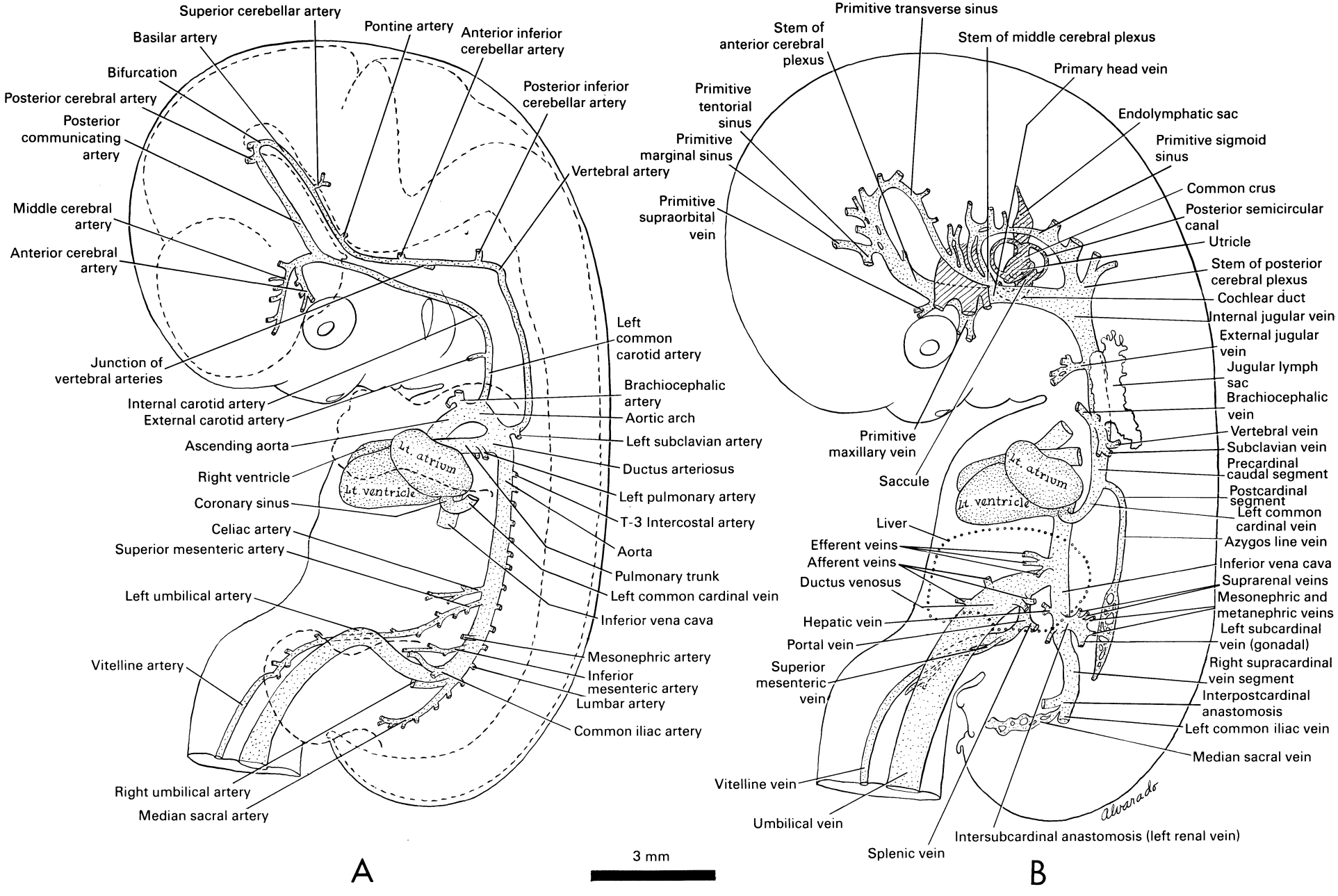
Superior cerebellar artery
Basilar artery
Pontine artery
Anterior inferior cerebellar artery
Bifurcation
Posterior cerebral artery
Posterior communicating artery
Posterior inferior cerebellar artery
Vertebral artery
Middle cerebral artery
Anterior cerebral artery
Junction of vertebral arteries
Left common carotid artery
Internal carotid artery
External carotid artery
Brachiocephalic artery
Aortic arch
Ascending aorta
Left subclavian artery
Rt. atrium
Rt. ventricle
Right ventricle
Ductus arteriosus
Coronary sinus
Left pulmonary artery
T-3 Intercostal artery
Celiac artery
Aorta
Superior mesenteric artery
Pulmonary trunk
Left umbilical artery
Left common cardinal vein
Inferior vena cava
Mesonephric artery
Vitelline artery
Inferior mesenteric artery
Lumbar artery
Common iliac artery
Right umbilical artery
Median sacral artery
A
3 mm
Primitive transverse sinus
Stem of anterior cerebral plexus
Stem of middle cerebral plexus
Primary head vein
Primitive tentorial sinus
Endolymphatic sac
Primitive marginal sinus
Primitive sigmoid sinus
Common crus
Primitive supraorbital vein
Posterior semicircular canal
Utricle
Stem of posterior cerebral plexus
Cochlear duct
Internal jugular vein
External jugular vein
Jugular lymph sac
Brachiocephalic vein
Primitive maxillary vein
Vertebral vein
Subclavian vein
Saccule
Precardinal caudal segment
Rt. atrium
Rt. ventricle
Postcardinal segment
Left common cardinal vein
Liver
Azygos line vein
Efferent veins
Afferent veins
Inferior vena cava
Ductus venosus
Suprarenal veins
Mesonephric and metanephric veins
Hepatic vein
Left subcardinal vein (gonadal)
Portal vein
Superior mesenteric vein
Right supracardinal vein segment
Interpostcardinal anastomosis
Left common iliac vein
Median sacral vein
Vitelline vein
Umbilical vein
Intersubcardinal anastomosis (left renal vein)
Splenic vein
Alvarado
B